Special Subscription Bonus

#10
p. 23
Tina

today's chiropractic®

November/December 1984

READ BY CHIROPRACTORS AROUND THE WORLD

THE MAGAZINE THAT REFLECTS THE LIFE PRINCIPLE IN CHIROPRACTIC

A10



Roy W. Sweat, D.C.



Thomas Sievert, D.C.

Chiropractic And The Vertebral Arteries

Part two of two

Roy W. Sweat, D.C.
Thomas Sievert, D.C.

About the Author: Dr. Roy W. Sweat's practice is in Atlanta, Georgia. He is a graduate of Palmer College. In 1952, he began a course of study specializing in the upper cervical occipital-atlanto-axial complex under Dr. John F. Grostic. Dr. Grostic chose him as an instructor at his seminars. Sweat completed a three-year program in chiropractic orthopedics from the National College and is an associate professor at Life College.

Dr. Sweat designed the cervical analysis instrument. In 1981 he created the program of chiropractic Atlas Orthogonality and wrote a series of five books. Dr. Sweat has designed a chiropractic adjusting instrument and also a series of x-ray machines and the orthogonal adjusting tables.

About the Author: Dr. Thomas Sievert attended the University of Wisconsin at Eau Claire, and graduated magna cum laude from Life Chiropractic College. Dr. Sievert interned under Dr. Roy Sweat from whom he received special training in orthogonal procedures of cervical adjustment. He also has done post graduate work in orthopedic testing, personal injury and impairment rating. Dr. Sievert is a diplomate of the National Board of Chiropractic Examiners. He maintains a practice at 2060 Collier Avenue, Fort Myers, Fla., 33901.

Anatomical Variants of the Vertebral Arteries

Hadley reports that tortuosities of the vertebral arteries were found on dissection in four of twenty-one cases. One case study presented a complete 360 degree loop between the transverse processes of C3 and C4.

The lower two right angle turns of the artery at C2 are common sites for aneurysms, according to Dr. J.A.W. Duckworth of the Canadian Chiropractic College. Hadley also describes an aneurysm-like condition which occurs, not uncommonly, within the body of the second cervical vertebra and can be visualized in both the AP and lateral projections. Clinically, the tortuosities of the vertebral arteries may render the artery vulnerable to compressive forces.

Another interesting variation in the vertebral artery is the high incidence of one artery being predominately larger than the other. Dissection of six brain stem specimens taken at random under the direction of Dr. Macon Weaver at Life Chiropractic College revealed the diameter of the left vessel to be significantly larger than the right in five of six cases. Leach reports studies citing seventy-one cases of assymetry of the vertebral arteries out of one hundred thirty post-mortem examinations. He also describes Junsi's study of eighteen patients with one vertebral artery congenitally smaller than the other: "In every case where unilateral blockage of the vessel produced symptoms, it was the larger artery which was blocked."

Mechanisms of Compression

The mechanisms of compression of the vertebral artery can occur by extremes of rotation and extension, hyperplastic posterior joints, neurocentral osteophytes, herniation of the nucleus pulposus and subluxations.

Salecki studied the effect of the large rotational movements of C1-C2 on the vertebral artery and found that 30 degrees of rotation produced kinking accompanied by stretching of the contralateral artery, which becomes more marked as the angle of rotation is increased. He also found that at 45 degrees rotation the ipsilateral vertebral artery begins to kink. If the blood flow is significantly decreased, symptoms of ischemia may be elicited.

Effects of extension on the vertebral artery have been cited by MacNab and Duckworth. Spondolytic formations in the mid-cervical spine put that region in an attitude of flexion resulting in a compensatory extension of the upper cervical spine to hold the head upright. Further extension may produce severe stretching of the vertebral artery between C1 and C2 or C1 and occiput because this will be the only area capable of further extension. Duckworth states that arteriosclerotic changes by way of calcium deposition occur in the elderly and predispose the vertebral arteries to injury due to their inability to stretch on extension. Cases exhibiting these types of degenerative conditions will be more susceptible to forces that hyperextend the spine and the ensuing symptomatology of vertebral artery compromise.

Hadley reports that hyperplastic arthrotic posterior joints can produce vertebral artery compromise. Extension of the cervical spine allows the superior articular facet to move forward and upward. Hyperplastic posterior joints may deflect the vertebral artery which will become exaggerated on extension and/or rotation, producing a decreased blood volume and subsequent symptomatology. He also states that atheromatous changes occur in the vessel over a period of time due to the constant deflection of the artery.

According to MacNab, cervical disc degeneration may also produce compression of the vertebral artery. A loss of disc height eventually leads to the jamming together of adjacent neurocentral joints, producing osteophytes. If an osteophytic spur from a neurocentral joint projects laterally, it may compress the artery as it issues from the transverse foramen, resulting in vertebral artery symptomatology.

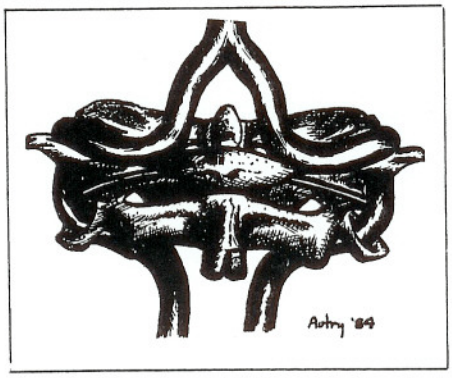

Diagnosis

Diagnosis of a suspected vertebral artery syndrome is obtained by the correlation of subjective symptomatology, case history and objective findings on x-ray and examination. Spondolytic deformities, hyperplastic arthrotic posterior joints, osteophyte formations and bone erosions can be noted on lateral AP and oblique projection. Suspected compromise of the vertebral artery can be verified upon physical examination by performing George's Cerebrovascular Craniocervical Functional Test for Ischemia. This test can be done standing or sitting; however, for the patient's safety, sitting is recommended. With eyes closed and arms stretched forward, the patient is instructed to rotate the head to one side and extend the neck, holding for 30 seconds. This should also be repeated on the opposite side. Sway of the outstretched arms suggests cerebral ischemia. If the symptoms of syncope, tinnitus, vertigo, or nausea are elicited, vertebral artery compromise should be suspected.

Conclusion

CHIROPRACTIC'S TIME HAS COME! Nearly all of the diseases and symptomatic conditions with which chiropractic has had miraculous results can now be documented by the medical profession as being possible with causes related to vertebral artery insult.

Chiropractic care of the cervical spine for vertibrobasilar symptomatology is necessary and extremely successful.

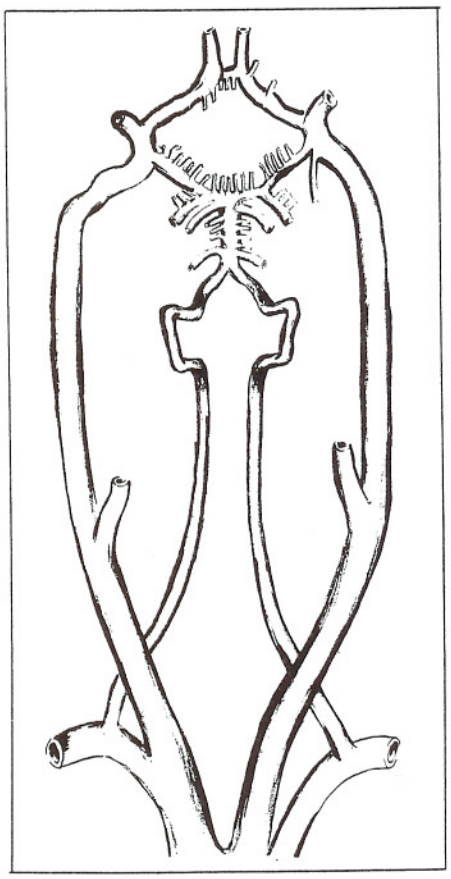

References

1. VonTorklus, Detlef. *The Upper Cervical Spine*, New York. Grule and Stratton, 1972, Page 22.
2. White and Panjabi. *Clinical Biomechanics of the Spine*, Philadelphia. Lippincott, 1978, Page 66.
3. Hadley, Lee A. *Anatomico-Roentgenographic Studies of the Spine*. Springfield. Thomas, 1964, Page 162.
4. Epstein, Bernard S. *The Spine - A Radiological Text and Atlas*, Philadelphia. Lea and Febiger, 1962, Pages 268-269.
5. Kabat, Herman. *Low Back and Leg Pain*, St. Louis. Green, 1980, Page 130.
6. Rotham and Simeone. *The Spine*, Philadelphia. Saunders, 1982, Pages 193, 456, 652.
7. MacNab, Ian. *The Cervical Spine*, "Symptoms in Cervical Disc Degeneration", Philadelphia. Lippincott, 1983, Pages 388-394.
8. The Cervical Spine Research Society. *The Cervical Spine* – MacNab. "Symptoms in Cervical Disc Degeneration", Philadelphia. Lippincott, 1983, Page 392.
9. Selecki, B.R. "The Effects of Rotation of the Atlas on the Axis: Experimental Work" Medical Journal, August, 1969. T:1012.
10. Duckworth, J.A.W. Dissection Seminar, Canadian Memorial Chiropractic College, Toronto, Canada, 1983.
11. Weaver, Macon. Dissection Seminar, Life Chiropractic College, Marietta, Georgia, 1984.
12. Netter, Frank H. *The Ciba Collection of Medical Illustrations* – Volume I "Nervous System" Published by Ciba, Page 24.
13. Wicke, Lothar. *Atlas of Radiologic Anatomy* – Third Edition. Urban & Schwarzenberg. Page 35, Vertebral Arteriogram (A-P Projection) Page 33, Vertebral Arteriogram (Lateral Projection).
14. Chusio, J.G. "Correlative Neuroanatomy and Functional Neurology," 16th Edition, Pages 45-46.