Tina

(2)

article 11 of 111

P. 16

Alternative

May/June 1983

In this issue:
Life College Development Plans &
Women In Chiropractic
Survey Results

today's chiropractic™

READ BY CHIROPRACTORS AROUND THE WORLD

THE MAGAZINE THAT REFLECTS THE LIFE PRINCIPLE IN CHIROPRACTIC

A-2

Atlas Orthogonal Aberrancy

A Dimension Beyond Symmetry

Part Two of Three

by Roy W. Sweat, D.C.

About the Author: Dr. Roy W. Sweat's practice is in Atlanta, Georgia. He graduated from Palmer College of Chiropractic in Davenport, Iowa, in 1950. In 1952, he began a course of study specializing in the upper cervical occipital-atlanto-axial complex under Dr. John F. Grostic in Ann Arbor, Michigan. In 1962, Dr. Grostic chose him to become an instructor at his seminars. Dr. Grostic died in 1964, at which time Dr. Sweat and four other doctors organized the Grostic Presentation Seminars and continued the specialized training program in Atlanta, Georgia. He wrote the Vertical Resultant Angles Book in 1970. In 1977, Dr. Sweat organized the Society of Chiropractors Orthospinology. He designed the cervical analysis instrument. In 1981 he created the program of Chirpractic Atlas Orthogonality and wrote a series of five books. Dr. Sweat has designed a chiropractic adjusting instrument and has developed a series of five different models. He has also designed a series of x-ray analysis instruments, which are in use today, and attachments for the x-ray machine and the orthogonal adjusting tables. He has completed a three-year program in chiropractic orthopedics from the National College of Chiropractic. Dr. Sweat is past president of the Georgia Chiropractic Association, and is an associate professor at Life Chiropractic College in Marietta, Georgia. The atlas orthogonality program was chosen by Dr. C. H. Suh, Ph.D of the University of Colorado and presented at the 13th annual Biomechanics Conference of the Spine. Dr. Sweat has been a member of the International Chiropractic Association (I.C.A.) since graduating from college and is a member of the National Research Committee of the I.C.A.

The occipital cervical spine is dramatically different from the remainder of the spine. Even the first two spinal nerves run dorsally to the intervertebral joints while all the others leave the foramen transversarium in front of the articular processes. It is the most transitional area of the spine and developmental abnormalities are quite common. Many variants, anomalies and malformations can occur. There are abnormalities of segmentation, aplasiasm, partial and complete dysplasias and dysraphic formations. These abnormalities assume a mutual relationship to each other in order to maintain the body in a vertical position. They are classified as occipital dysplasia (Schmidt and Fischer 1960) or sub-occipital dysplasia (von Torklyus 1963, 1964).

In chiropractic, we use osteological procedures to remove neurological insults. The osteology and neurology are associated and contiguous, but is possible to have abnormal right and left cranium sizes, lateral masses, posterior arches, and axis bodies. Innate intelligence tries to adapt these structures to keep the body as vertical as possible. Sometimes, the land marks used to related these structures to vertical and horizontal positions are altered due to abnormalities, and must be corrected for use in chiropractic adjusting procedures. However, we question any procedure that moves the cranium or the cervical spine away from vertical, or moves the atlas away

A-12

Fig. 1

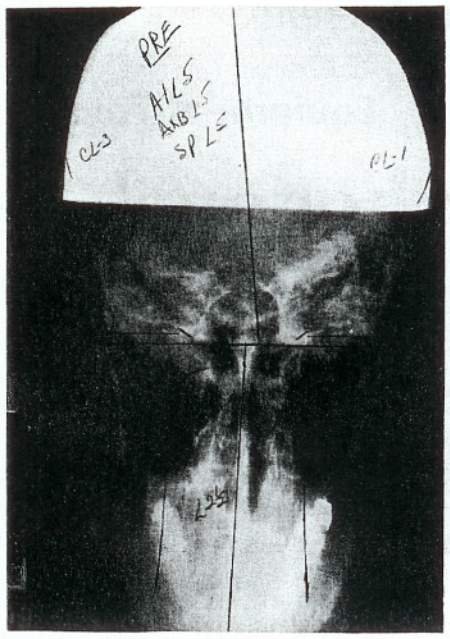

Fig. 3a

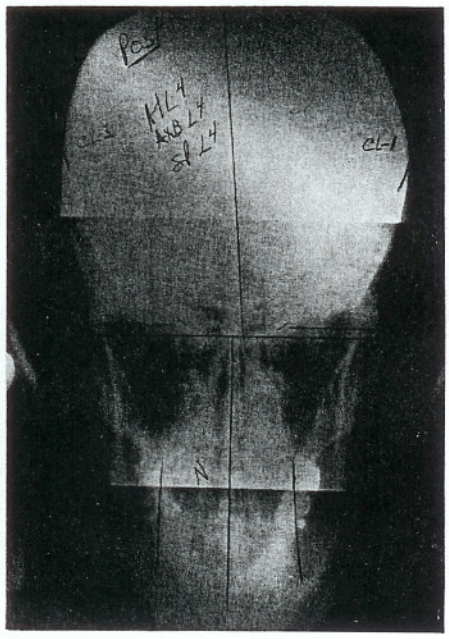

Fig. 3b

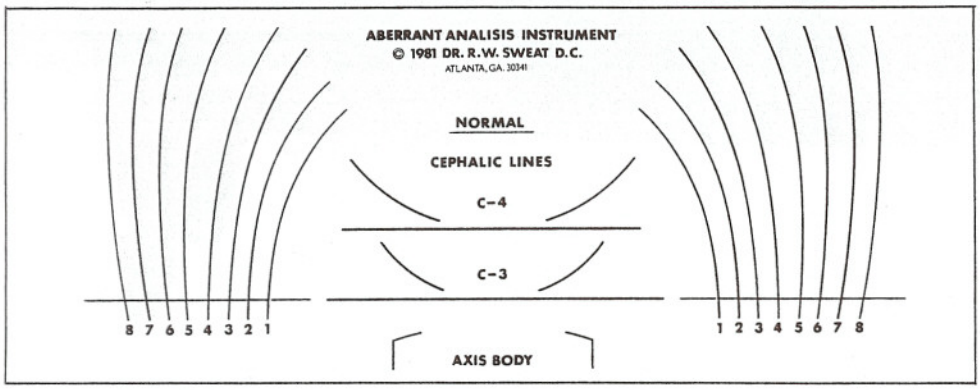

Fig. 2

from the horizontal positon.

The Lateral View

A three dimensional presentation of the cervical spine is necessary to form a basis for radiological, anatomical, and pathological programs. Chiropractors are familiar with cervical abnormalities as presented by Rothman and Simeone, Chamberlain, Dolan, McGregor, McRae, Spillane and von Troklus. The lateral view is the most important in revealing gross abnormalities and pathology. Sagittal views of the occipital condyles, atlas, axis, and the lower cervical vertebrae are vitally important.

In atlas orthogonal programs, we use the lateral view to establish the atlas transverse process in its relationship to the mastoid, and the ramus of the mandible for contact purposes in the chiropractic adjustment. A base line is established for height, rotational vectors and the patient table placement (Fig. 1).

The Nasium View

The cervical analysis instrument is designed to relate one side of the cranium to the opposite side and find a center line between these two sides that represents the center of the head. This is then measured to the atlas plane line to see how the head has moved from vertical or neutral and how the atlas has moved laterally on the occipital condyle. The side of the acute angle is then listed as atlas laterality.

The cephalic lines on the analysis instrument are drawn from the various sizes of the cranium -- large, medium, and small. The small circular slashes along the cephalic lines are used in placing and finding the correct lines.

We designed an aberrant analysis x-ray instrument (Fig. 2) that took the cephalic lines from the cervical analysis instrument and listed them numerically so that one side of the cranium could be measured with a numbered line. We put that same numbered line on the opposite side to see if the two lines are equal, curved the same, or had the same elipse. When the two are equal, the center line is true; when they are not equal, the center line is not true and does not represent the vertical center of the skull. The cephalic line that curves the most will make the center line incorrect to the opposite side and will average two degrees for each line variance. With abnormal cephalic lines, an atlas right one degree may be a true atlas left one degree or an atlas left four degrees may be a true left six degrees or a true left two degrees. Post x-rays may still measure

A-2

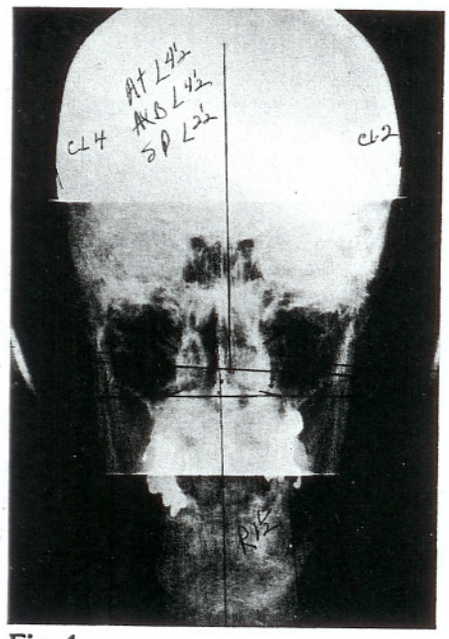

Fig. 4

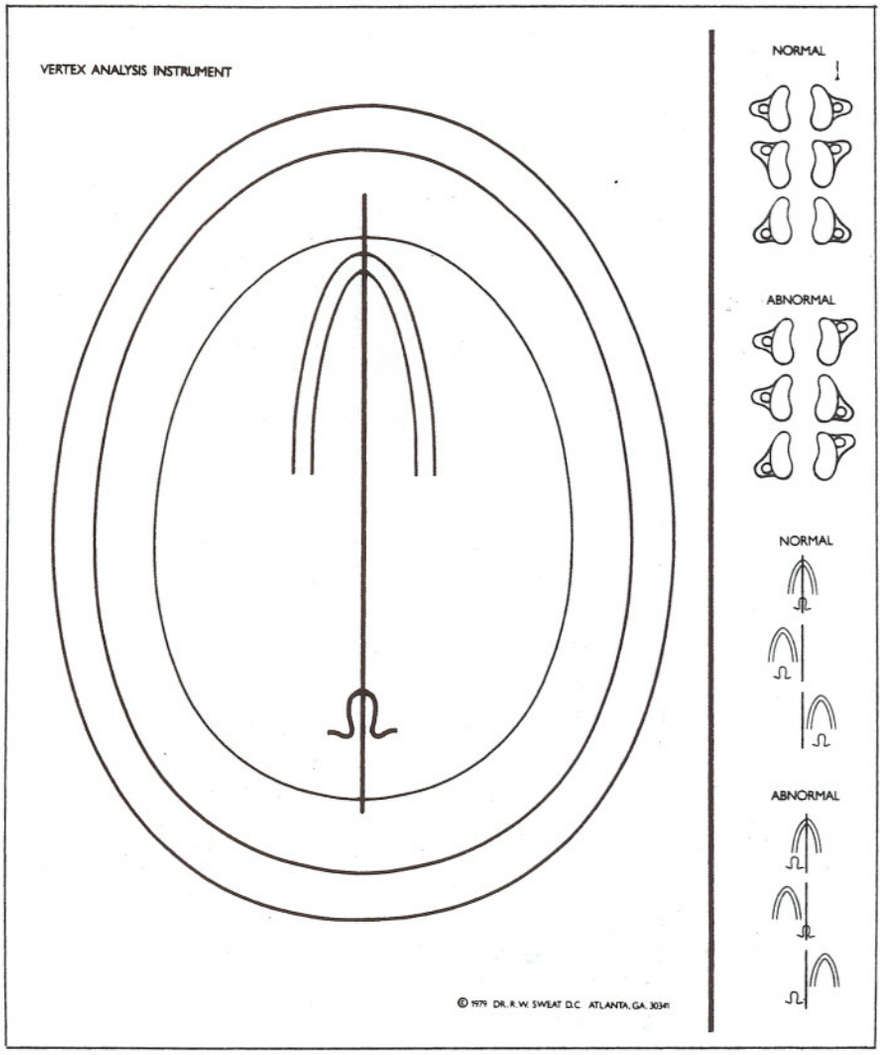

Fig. 5

some degree from vertical, but may be at a neurological zero (Fig. 3). We find the cephalic line are aberrant 25 percent to 30 percent.

Two of the atlas' three growth centers are in each lateral mass. The posterior arch is usually in the center or slightly above center of the lateral mass. It must be x-rayed at a right angle to the lateral mass and is used as a landmark for the atlas. The lateral masses must be measured for their vertical height to see if they are equal. The posterior arch may be in the neutral center of each lateral mass, but measure improper from horizontal. The posterior arch must measure the same distance on each side to the lateral inferior tips of the lateral masses. The superior and inferior facets may be vertically abnormal to their opposite sides and the superior facets are the most abnormal. The posterior arch is the most accurate landmark with the lateral tips of the inferior facets the second most accurate. When the posterior arch is abnormal, we use the inferior facets of the atlas as our landmarks (Fig. 4). The posterior arch is abnormal 10 percent to 15 percent.

Each of the occpital condyles has a growth center. One side can grow lower than the opposite side and can curve more than the opposite side. When one condyle is lower than the other, innate intelligence attempts to adapt and keep the body as vertical as possible by having one lateral mass vertically larger than the other, or one side of the axis body higher. When the condyles are abnormal, it is condylar hypoplasia. The condyles can be measured according to Schmidt and Fischer (1960). On the average, the angle is 125 degrees. This relates to a three-condylar circle on the cervical analysis instrument. In a number of cases of condylar hypoplasia, the angle was increased to 160 degrees. This relates to a condylar circle of eight on the cervical analysis instrument. Usually, the atlas plane line is abnormally high on the side of the high condyle and/or the side of the high axis body. Additional height vectors must then be added to the line of drive. On post x-rays, the atlas plane line will not reduce to horizontal or normal, but may be at a neurological zero which is normal for that patient. We find the condyles are abnormal 30 percent to 40 percent, and the axis body is abnormal 20 percent to 25 percent (Fig. 4).

The condyle and superior facet of the atlas act as mechanical incline planes and the steeper the planes, the more lateral and medial these structures subluxate from trauma. The atlas will usually subluxate laterally on the side of the high condyle or the steep, more curved condyle. White and Panjabi state there are eight degrees of lateral movement between the occipital condyles and the superior facets of the atlas. Lewit and Krausová state that there is a maximum of 14 degrees and a minimum of one

A-2

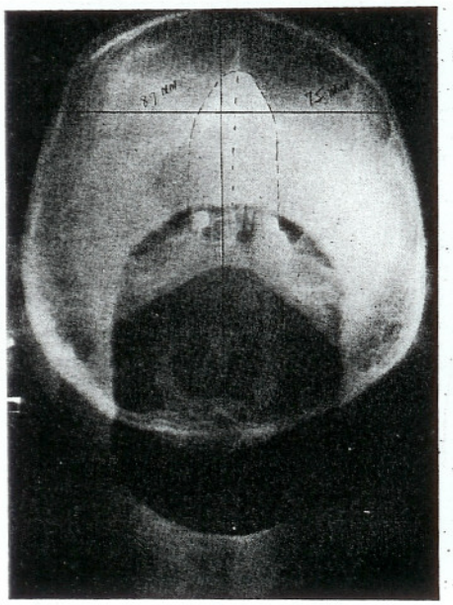

Fig. 6

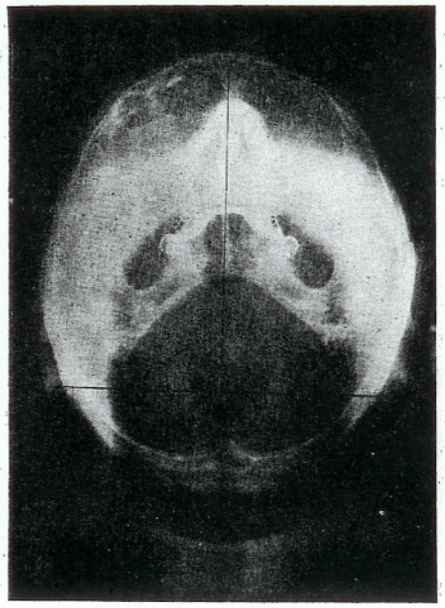

Fig. 7

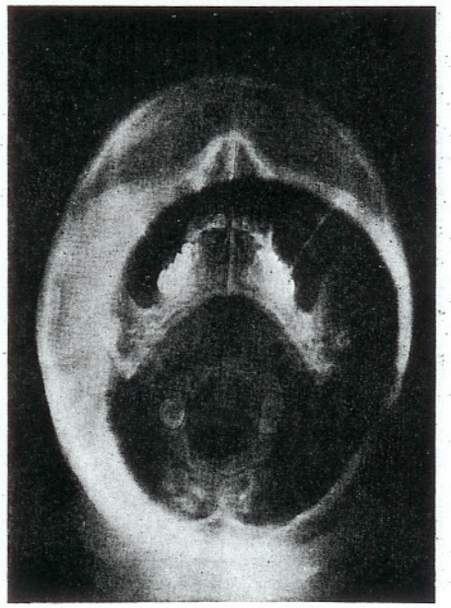

Fig. 8

degree with 5.5 degrees being the average.

We find where there is more than five degrees of lateral movement between the atlas and the occipital condyles, some abnormalities are suspected. Post x-rays will show some remaining misalignments from the orthogonal position, but that may be a neurological zero.

These aberrant conditions can cause a cervical spinal instability. Some of these patients will respond favorably to chiropractic adjustments, but will not hold or maintain adjustments and will have to be adjusted more often. Some of these abnormal conditions should not be put on cervical adjusting programs.

The Vertex View

In the vertex view, we measure the rotation of the atlas on the occipital condyles. We construct a neutral line or center cranial line. The frontal groove is our anterior landmark and the center of the foramen magnum is the posterior. A vertex analysis instrument (Fig. 5) is placed over the cranium to find a center line to see if the frontal groove and center of the foramen magnum are in a neutral relationship. The vertex instrument is more accurate than the frontal groove (Fig. 6) and foramen magnum line (Fig. 7). The frontal groove is abnormal 40 percent and the foramen magnum is abnormal 10 percent to 15 percent.

The landmarks we use for the atlas are the foramina transversarium and the lateral masses. The foramina transversarium are formed by the anterior and posterior roots. They should be equal in size and in the longitudinal center of the lateral masses (Fig. 8). The lateral masses are more accurate than the foramina transversarium, which are abnormal 30 percent to 40 percent.

Gray's Anatomy does not list any muscles responsible for producing rotational movement between the occipital condyles and the superior atlas facets. It lists muscles only for flexion, extension, and lateral flexion. The obliquus capitis superior muscle has some function of rotation, but this is negligible. In dissection, this muscle does not run obliquely but almost straight vertically from the upper surface of the atlas transverse process to the occiput. Perhaps it is misnamed.

White and Panjabi state that there is an absence of rotation between the occiput and C-1.

"Rotation is prevented by the geometric anatomy of the articulation of the Occp-C1 joint, and the two structures move as one unit about the y-axis. The joint surfaces are cup-shaped or arcuate in the sagittal plane, with the arcuate occipital articulation fitting into the cup of C1."

Rothman and Simeone state that the occipital-atlantal joint rotation is negligible. Von Torklus states that there is no rotational movement between the occiput and the atlas.

"It is a turntable movement with the atlas acting as a disc between the head and the axis and that the head and atlas rotate together on the superior axis facets."

We find that the atlas and occipital condyle rotation is only three to five degrees. If higher that this, it is usually abnormal condyles. These condyles are not equal in their lateral aspect on the foramen magnum. The adjustment rotational angle must be at the abnormal position, but the rotation may only reduce three to five degrees from the original position, or within its articular bed, and that may be normal for the patient. The rotational vector of the atlas, in relationship to the occipital condyles, must be known to adjust the atlas back down and under the occipital condyles. We find the rotational vector is more critical with less tolerance that the height vector.

Conclusion

Chiropractors must be the first to say to the scientific community that there can be osteological zeros that are not neurological zeros. Because of osteological programs to remove neurological insult; the doctor of chiropractic that is skilled at clinical findings in the pre and post neurological and orthopedic examinations (such as scan-

A-2

ning palpation and leg check to see if the neurological insult has been removed) will service the patient best. Many patients who have not responded to chiropractic care previously, do so when aberrancies are considered and vectors changed.

In 30 years of an exclusive atlas practice we have found the osteological and neurological findings are correct 60 percent. We have aberrant analysis instruments and clinical programs to find and allow for aberrancies. Roentgenological findings must be correlated with clinical findings. ■

REFERENCES

1. *Clinical Bio-Mechanics of the Spine.* W.E White and M.M. Panjabi. Lippincott Compan
2. *The Spine.* Volumes 1 and 2. Second Editio Rothman and Simeone.
3. *The Upper Cervical Spine.* Detlef von Torklus and Walter Gehle.
4. *The CIBA Collection of Medical Illustrations.* Nervous System. Volume 1. Frank H. Netter.
5. *Gray's Anatomy.* 35th Edition. W.B. Sanders Company.
6. *The Occipital Dysplasia.* H. Schmidt and E. Fischer. 1960.
7. *Mechanisms of the Cervical Spine.* K. Lewit and L. Krausova'. 1964.
8. Dr. Roy W. Sweat, D.C. Case History Studies, Pre and Post X-Rays.
9. Dissection Seminar, National Chiropractic College. Chicago, Illinois, December, 1982.

What You Should Do When Involved In A Malpractice Suit

by Samuel E. Spital

1. If served with a lawsuit, a "90-Day Notice" or subpoena for records, call an attorney experienced in malpractice cases at once.
2. If you have malpractice insurance, call your carrier immediately.
3. Set aside ample time and give this matter priority.
4. Obtain copies of all pertinent medical and hospital records.
5. Prepare a detailed narrative of the facts and circumstances surrounding the case.
6. Protect yourself by taking an "offensive" position (the best defense is a strong offense).
7. Even though you are assigned counsel by a malpractice carrier, you have the right to consult your own attorney. With the aid of an attorney experienced in malpractice cases, you should determine if there are any potential conflicts of interest as a result of other defendants in the case, or liability/exposure beyond the limits of your insurance.
8. With the aid of your personal legal counsel, you will want to consult with several expert witnesses.
9. You should request that your personal legal counsel monitor the case and report back to you regularly regarding its status.
10. Do not consent to a settlement nor withhold your consent to a settlement without first reviewing the matter with legal counsel experienced in malpractice cases, inasmuch as a settlement or judgement over $30,000.00 must be reported.

For more information, write the law offices of Samuel E. Spital, 1200 Third Avenue, Suite 1200, San Diego, California 92101.