THE AMERICAN CHIROPRACTOR

MAGAZINE OF THE CHIROPRACTIC PROFESSION

INTERVIEW
Donald P. Kern, D.C.

INDEX CHIROPRACTIX
The Aluminum Controversy

NUTRITION UPDATE
Evening Primrose Oil and Gamma Linolenic Acid

FEBRUARY 1988

FEBRUARY 1988 THE AMERICAN CHIROPRACTOR

A28

Minimum Force vs. Moderate Force In The Occipital-Atlanto-Axial Subluxation Complex (OCP-C1-C2)

by Roy W. Sweat, D.C.

Occipital-Atlanto-Axial Complex (OCP-C1-C2) are diarthrodial (freely movable) joints. They are synovial joints and have no intervertebral disc. The remaining vertebral bodies from the axis down to the first sacral articulation are united by intervertebral discs and are classified as symphyses. (Fig. 1)

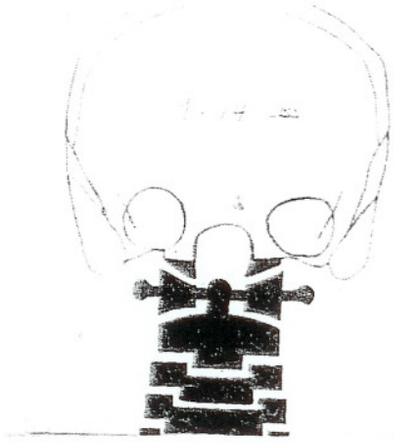

Fig. 1

Adjusting Vertebral Subluxations Within Their Normal Range of Motion

A subluxation is a fixed misalignment within the normal range of motion of the vertebrae. A luxation is a misalignment outside of the vertebrae's normal range of motion which is not our chiropractic service. We must move the vertebrae within their normal range of motion and return them to their normal or neutral position.

The Atlas Subluxation

The atlas vertebra, in its articulations with the occipital condyles, the Foramen Magnum or Great Opening, supporting the weight of the head, articulations below with the axis facets and the movements of the spinous process, the cervical spinal balance with its relationship to the dorsal and lumbar spine, is the most complex area in the spine.

Dr. John F. Grostic stated in his seminars in Ann Arbor, Michigan, that "The atlas area has the most wedges, circles, incline planes, fulcrums, and levers than any other area of the spine."

Gray's Anatomy states, "The cervical spine has more range of motion than any other area of the spine."

In Clinical Biomechanics of the Spine, it is stated, "The occipital-atlanto-axial joints are the most complex joints of the axial skeleton, both anatomically and kinematically."

J.V. Basmajian, M.D. states in Muscles and Movements, "The vertebral column, the great stabilizer of the trunk, also embodies mobility. However, this mobility is limited by the various ligaments, articular facets, spinous processes, intervertebral discs and other indirect factors. Although the total range of movement of the spine is wide, movement between adjacent vertebrae is quite limited, except for the first two cervical vertebrae (the atlas and axis)."

Coefficient of Friction

"Definition. The ratio of tangetial force to the normal interbody compressive force required to initiate a sliding motion between two bodies.

"The tangential component in the healthy joints is generally very small, about 1 per cent of the normal component. This is due to very low joint friction.

"The value of the coefficient of friction in the animal ankle joint is .005." (Above quoted from Clinical Biomechanics of the Spine).

Rothman and Simeone, M.D.'s state in Spine, "At the occipito-cervical joints, 40 per cent of the normal motion of the cervical spine occurs in flexion and extension."

Occipital-Atlanto Joint (OCP-C1)

This area is freely movable but in small increments. Clinical Biomechanics of The Spine states that "flexion/extension has 13 degrees (moderate) of motion, and axial rotation has 0 degrees (negligible) of motion."

CONTINUED ON PAGE 23

CONTINUED FROM PAGE 22

Spine magazine Volume 12, Number 3, April, 1987, states that rotation at occiput-atlas was 4.35 degrees to the right and 5.9 degrees to the left. Spine states further in Volume 12, Number 8, 1987, that the mean value and range of rotation between OCP-C1 in 26 subjects had a mean of 1.0 degrees. The mean lateral displacement of the atlas with respect to the foramen magnum was 4.4 mm, with a range of 3-6 mm.

Detlef Von Torklus in The Upper Cervical Spine states that, "rotation between the occiput and the atlas is negligible. The atlas acts as a turntable between the head and the axis. The lateral tilt in the occipital cervical joint is limited and it averages 5.5 degrees."

We find the normal range of lateral flexion motion between the atlas and the occipital condyles is approximately 5 degrees without abnormalities.

Fig. 2

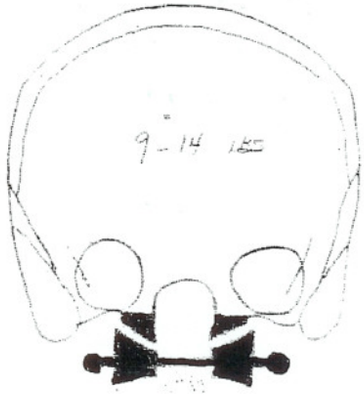

Fig. 3

The normal range of rotational motion between the atlas and the occipital condyles is approximately 3 to 5 degrees without abnormalities. Converting 5 degrees to lineal measurement on a 3 inch diameter circle is 1/8 inch or 3.18 mm. (Fig. 2 and Fig 3)

Atlanto-Axial Joint (C1-C2)

White and Panjabi state in Clinical Biomechanics of The Spine, "The C1-C2 articulation is the most complex and difficult one to analyze."

Most all authorities agree with White and Panjabi in their findings that in the atlanto-axial joint (C1-C2) flexion/extension has 10 degrees (moderate) of motion, lateral bending has 0 degrees (negligible) and axial rotation has 47 degrees (extensive) of motion. (Fig. 4)

The first instrument we made had settings varying from 1/2 inch to 1/16 inch thrust depth. The second

CONTINUED ON PAGE 24

CONTINUED FROM PAGE 23

series of instruments had a 1/4 inch to 1/16 inch thrust depth, which was 50 percent less depth than the original. The next series of instruments had settings varying from 1/8 inch to 1 mm depth thrust, which is 50 percent less depth. The next series of instruments we made was a percussion instrument with no forward excursion. This instrument utilized a 15 pound solenoid. The next series of instruments we made utilized a 6 pound solenoid. The next series of instruments utilized a 1.8 pound solenoid which is our present atlas orthogonal percussion adjusting instrument.

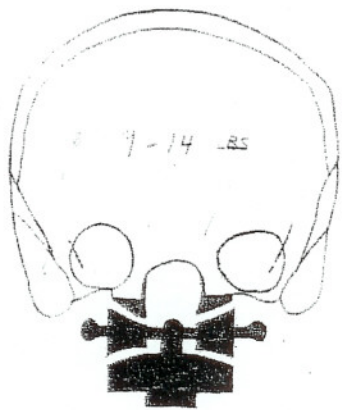

Fig. 4

Conclusion

Adjusting the atlas area is not a simple procedure. It is as delicate as the most complicated surgery and does require an endless process of study and discipline.

In my opinion, we need a new generation of chiropractors using minimum forces in the Occipital-Atlanto-Axial area (OCP-C1-C2) and research to find what type of minimum force is most effective and accurate.

References

1. White, W.W. and M.M. Panjabi, CLINICAL BIO-MECHANICS OF THE SPINE, Lippincott Company, Pages 65, 66, 196, 198, 462
2. GRAY'S ANATOMY, 25th Edition, W.B. Saunders Company, Page 234
3. Detlefvon Torklus and Walter Gehle, THE UPPER CERVICAL SPINE, Pages 10, 69
4. Basmajian, J.V. MUSCLES AND MOVEMENTS, Page 218
5. Medical Department Harper & Row Publishers, SPINE magazine, Volume 12, Number 3, April 1987, Page 197
6. Medical Department Harper & Row Publishers, SPINE magazine, Volume 12, Number 8, October 1987, Pages 732, 733
7. DR. JOHN F. GROSTIC'S SEMINARS, Ann Arbor, Michigan
8. Dr. Roy W. Sweat, CASE HISTORY STUDIES, pre and post x-rays
9. Rothman and Simeone, THE SPINE, Volume 2, Second Edition, Page 662.

Dr. Roy W. Sweat is a 1950 graduate of Palmer College of Chiropractic. Dr. Sweat has been a member of the International Chiropractic Association since graduating from college and is a member at the present time. He has been appointed to the National Research Committee of the International Chiropractic Association. Dr. Sweat is also an associate professor at Life Chiropractic College in Marietta, GA, and is associated with their research program there. He is a past president of the Georgia Chiropractic Association.