LIFE COLLEGE
TENTH ANNIVERSARY

11

Tina

P. 23

Commission
Subpoena

today's chiropractic®

January/February 1985

READ BY CHIROPRACTORS AROUND THE WORLD

THE MAGAZINE THAT REFLECTS THE LIFE PRINCIPLE IN CHIROPRACTIC

Scanning Palpation

Cervical Spine



by Roy W. Sweat, D.C.

About the Author: Dr. Roy W. Sweat's practice is in Atlanta, Georgia. He is a graduate of Palmer College. In 1952, he began a course of study specializing in the upper cervical occipital-atlanto-axial complex under Dr. John F. Grostic. Dr. Grostic chose him as an instructor at his seminars. Sweat completed a three-year program in chiropractic orthopedics from the National College and is an associate professor at Life College.

Dr. Sweat designed the cervical analysis instrument. In 1981 he created the program of chiropractic Atlas Orthogonality and wrote a series of five books. Dr. Sweat has designed a chiropractic adjusting instrument and also a series of x-ray machines and the orthogonal adjusting tables.

The spinal nerves are formed by the union of ventral and dorsal spine nerve roots which are attached in series to the side of the spinal cord. There are 31 pairs of these nerves grouped as follows: 8 cervical, 12 thoracic, 5 lumbar, 5 sacral, 1 coccygeal.

"The course of the first two spinal nerves runs dorsally to the intervertebral joints while all others leave the foramina intervertebralia in front of the articular processes." (Detlef von Torklus and Walter Gehle.)

"The absence of posterior articulations between the head and atlas and between the atlas and axis leaves the first two nerves without actual intervertebral foramina." (Ruth Jackson.)

The first cervical nerve exists from the vertebral canal between the occipital bone and the atlas. The first cervical dorsal ramus is larger than the ventral ramus, and emerges superior to the posterior arch of the atlas and inferior to the vertebral artery. It enters the suboccipital triangle and supplies the muscles which bound this region, the rectus capitis posterior major and the superior and inferior oblique; it gives branches also to the rectus capitis posterior minor and the semispinalis capitis. A filament from the branch to the inferior oblique joins the dorsal ramus of the second cervical nerve. The nerve occasionally gives off a cutaneous branch which accompanies the occipital artery to the scalp, and communicates with the greater and lesser occipital nerves.

The superior articulation of the atlas overhangs the artery and nerve root posteriorly – an important anatomical fact to be considered under the mechanism of cervical nerve root irritation . The ventral ramus of the first cervical nerve appears above the posterior arch of the atlas vertebra and passes forward laterally to its lateral mass, and medially to the vertebral artery. It supplies a branch to the rectus lateralis, and emerging on the medial side of that muscle, descends in front of the transverse process of the atlas and behind the internal jugular vein, and joins with the ascending branch of the second nerve.

The second cervical dorsal ramus is slightly larger than the ventral and all the other cervical dorsal rami. It emerges between the posterior arch of the atlas and the lamina of the axis below the inferior oblique. It supplies a twig to this muscle, receives a communicating filament from the dorsal ramus of the first cervical and then divides into a large medial and a small lateral branch. Its close proximity to the lateral joint and the posterior arch make it potentially vulnerable to irritation or compression.

The medial branch (also called the greater occipital nerve) ascends obliquely between the inferior oblique and the semispinalis capitis, and pierces the latter muscle and the trapezius near their attachments to the occipital bone. It is then joined by a filament from the medial branch of the dorsal ramus of the third cervical, and ascending in the occipital area with the occipital artery, divides into branches which communicate with the lesser occipital nerve and supply the skin of the scalp as far forward as the vertex of the skull. It gives muscular branches to the semispinalis capitis and occasionally a twig to the back of the auricle.

The lateral branch supplies filaments to the splenius, longissimus capitis and semispinalis capitis and is often joined by the corresponding branch of the third cervical.

The ventral ramus of the second cervical nerve issues between the vertebral arches of the atlas and axis and runs forward between the transverse processes of these two vertebrae. It passes in front of the first posterior intertransverse muscle, emerging on the lateral side of the vertebral artery between the longus capitis and levator scapulae. But when the scalenus medius takes origin from the transverse process of the atlas, it intervenes between the nerve and the levator scapulae. It divides into an ascending branch which joins with the first cervical nerve and a descending branch which unites with the ascending branch of the third cervical nerve.

C-1 and C-2 spinal nerves are unique in their peripheral distribution. They do not travel through an intervertebral foramen. They are associated with diarthrodial (freely moveable) joints. The occipital condyles and the superior

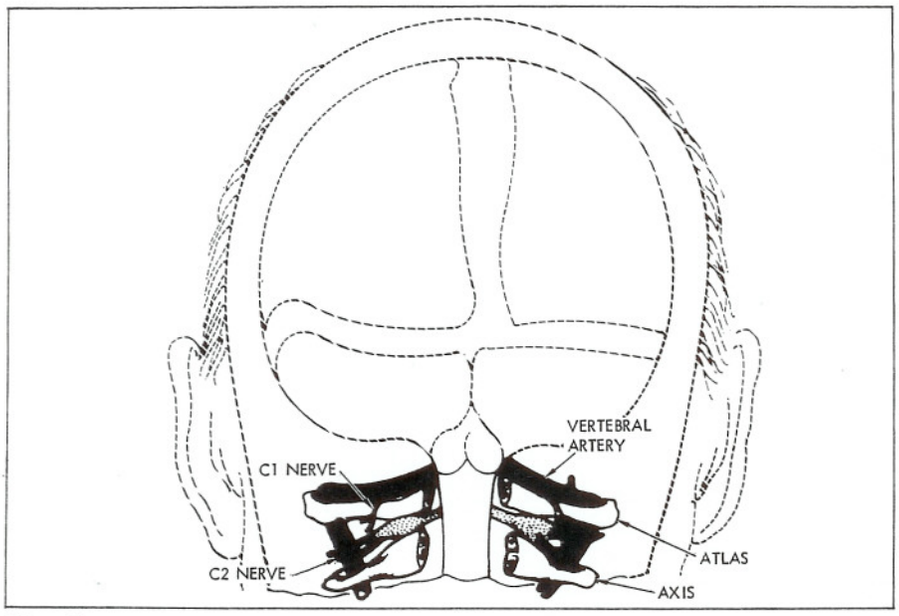

Fig. 1

atlas facets are synovial joints and have no intervertebral discs. The inferior atlas facets and the superior axis facets are synovial joints and have no intervertebral discs. This area has the greatest range of spinal motion. The remaining vertebral bodies from the axis down to the first sacral articulation are united by intervertebral discs and are classified as symphyses. (Fig. 1)

Scanning Palpation

Scanning palpation is the tactile examination of the cervical spine with objective findings of muscular spasms, contractions, enlargements, swelling or osseous protuberances. Subjective findings will be extreme tenderness, pain, hypersensitivity, hyperirritability and neurological insult in the positive palpated areas.

Begin at the atlas and examine down to the 7th cervical vertebra on each side. They are listed as:

C-1 R_____L_____
C-2 R_____L_____
C-3 R_____L_____
C-4 R_____L_____
C-5 R_____L_____
C-6 R_____L_____
C-7 R_____L_____

They are graded as 1, 2, or 4; with 3 being the most severe.

The doctor begins his examination with his fingers medial to the sternocleidomastoideus muscle area and lateral to the center of the posterior arch and cervical spinouses. He then begins at occiput and C-1 with the middle finger on one side and continues down to C-7. Then, he uses the thumb on the opposite side at occiput and C-1 level down to C-7. (Fig. 2)

The grades 2 or 3 will always relate to a short leg and the patient needing an adjustment. With a grade 1, or less, the leg should be even, or satisfactory, and the patient not needing an adjustment. The same grade will return to the same area when the patient needs another adjustment.

When the scanning changes dramatically from previous scanning, usually there has been some new trauma and the patient's adjustment listings may have changed. Post-scanning examination should reveal 80 to 100 per cent improvement in reduction of the findings after the proper adjustment. When the scanning examination does not reveal reductions, it usually indicates errors in the adjustment or the subluxation listings.

Neurological Insult and Trigger Points

"Trigger point, trigger zone, trigger spot, trigger area: a focus of hyperirritability in a tissue that, when compressed, is locally tender and, if sufficiently hypersensitive, gives rise to referred pain and tenderness, and sometimes to referred autonomic phenomena and distortion of proprioception. Types include myofascial, cutaneous, fascial, ligamentous and periosteal trigger points." (Janett G. Travell and David G. Simons.)

Sensory, motor and autonomic neurological insult and myofascial trigger points can produce neuromuscular dysfunction and disease.

Conclusion

In the atlas orthogonal program, the scanning palpation correlates with the supine leg check to determine when to adjust and when not to adjust the patient. When the scanning palpation is positive in the C-1 and C-2 area it relates to direct neurological insult or neurological insult with resultant trigger point. When the scanning palpation is positive from C-3 to C-7 it relates to muscle spasms, contractions, trigger points, and posterior zygapophyseal joint compression.

The doctor of chiropractic is extensively trained and is a specialist in this important science of scanning palpation examination. ■

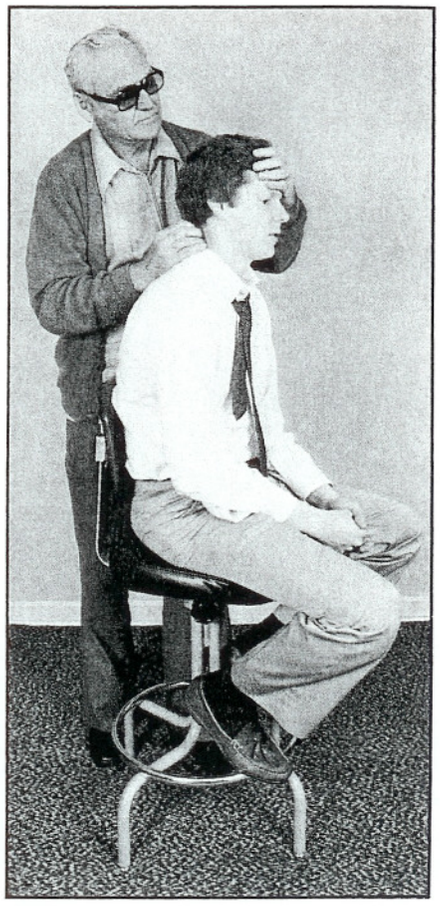

Fig. 2

References

1. von Torklus, Detlef. *The Upper Cervical Spine,* New York. Grune & Stratton, 1972, Page 1.
2. Jackson, Ruth and Thomas, Charles C. *The Cervical Syndrome,* Springfield, Illinois. Pages 47-48.
3. Travell, Janet G. and Simons, David G. *Myofascial Pain and Dysfunction,* Baltimore and London. Williams & Wilkins, Page 4.
4. Warwick and Williams. *Gray's Anatomy,* Philadelphia. W.B. Saunders Co., Pages 1030, 1032, 1034, 388 and 411.
5. Cailliet, Rene. *Neck and Arm Pain.* Page 25.
6. Weaver, Macon. "Dissection Class," Life Chiropractic College.
7. Pernkoph. *Atlas of Topographical and Applied Human Anatomy, Volume 1: Head and Neck.* Urban & Schwarzenberg, Page 50.